

# Diagnosing and Treating Corneal Dystrophy

Understanding corneal dystrophies can help you manage these challenging patients.

By Gregory W. DeNaeyer, OD

Everyone who fits contact lenses will encounter patients who have corneal dystrophy. A few of these dystrophies are common and easily recognized, while others are rare and more difficult to diagnose. Beyond making a diagnosis, managing patients to maximize comfort and vision can be challenging.

The first step in diagnosing corneal dystrophy is differentiating it from corneal degeneration. A corneal dystrophy is an inherited, bilateral disorder that usually has an early age of onset. A corneal degeneration is a late-onset, sometimes unilateral disorder that results from inflammation or systemic disease.

Corneal dystrophies primarily affect a single corneal layer, and this is the next clue in determining a diagnosis. When assessing a patient at the slit lamp, it's crucial to take time to examine the depth of the lesions. You can accomplish this by turning the slit lamp beam so that you can view the cornea in cross-section.

The next clue is to note any pattern the lesions may display. Often clinicians will try to make a diagnosis solely based upon the dystrophy's pat-

tern, but the severity and expression and stage of the dystrophy can alter its clinical picture among individuals. Lastly, because dystrophies are inherited mostly as autosomal dominant disorders, a careful family history can help to confirm the diagnosis.

If in doubt, a referral to a corneal specialist may be necessary for confirmation or assistance. A secondary benefit to a referral is that the patient and surgeon will already have a working relationship in case surgical intervention is necessary as the dystrophy progresses.

The following is a brief description of the more common corneal dystrophies, classified by corneal layer. Table 1 lists the discussed dystrophies with their differential diagnosis and treatment.

## Epithelium


*Meesmann's Corneal Dystrophy* is an autosomal dominant dystrophy that can present in the first decade of life and progress into adulthood. It's characterized by diffusely distributed intraepithelial cysts that are usually concentrated in the interpalpebral Zone 2 (Figure 1). These vesicular lesions are mimicked by microcystic



Dr. DeNaeyer is the clinical director for Arena Eye Surgeons in Columbus, Ohio. His primary interests include specialty contact lenses and glaucoma. He may be reached at [gdenaeyer@arenaeyesurgeons.com](mailto:gdenaeyer@arenaeyesurgeons.com)

edema secondary to contact lens wear.

The prognosis for these patients is mostly good. In severe cases the cysts can rupture on the surface causing irritation and photophobia. Bandage contact lenses can be invaluable to patients during these episodes. Vision can be permanently affected if secondary scarring results with vesicular rupture. These patients rarely require surgical intervention.



**Figure 1. Retroillumination of intraepithelial microcysts in Meesmann's corneal dystrophy.**

**Epithelial Basement Mem-**

**brane Dystrophy (EBMD)**, also referred to as Map-Dot-Fingerprint dystrophy or Cogan's microcystic epithelial dystrophy, is common in clinical practice. Patients may have a moderate-to-severe autosomal dominant version or may be sub-clinical and manifest EBMD changes secondary to trauma, including surgery. LASIK surgery is an absolute contraindication for a patient who has EBMD because it will significantly worsen its severity.

EBMD is characterized by either geographic epithelial changes called maps (Figure 2), opaque irregular opacities called dots, or concentric irregular lines referred to as fingerprints. This dystrophy re-

sults from a thickened basement membrane. If these changes are mild and the patient is asymptomatic, regular follow-up care is all that is necessary. Occasionally these epithelial changes are more severe and will cause an irregular surface resulting in decreased visual acuity.

Another complication is that an abnormal basement membrane can weaken epithelial attachment and result in recurrent corneal erosions (RCEs). You can use a bandage contact lens

to initially treat an abrasion following an erosion episode until re-epithelialization occurs. Occasionally, debridement of loose and irregular tissue may be necessary for resolution.

To prevent further erosions, hypertonic solutions during the day or hypertonic ointments at night may be necessary for up to three months. If this fails to prevent RCE, then surgical intervention such as anterior stromal puncture or phototherapeutic keratotomy (PTK) may be necessary. Incidentally, PTK may also be able to correct the patient's ametropia, as this is essentially a form of photo-refractive keratectomy (PRK).

TABLE 1

**List of Major Corneal Dystrophies by Layer**

	MODE OF INHERITANCE	AGE OF ONSET	PATTERN	TREATMENTS
<b>EPITHELIUM</b>				
EBMD	Autosomal Dominant	Variable	Map, Dot or Fingerprints	BSCL, Hypertonics, curettage, PTK, ASP
Meesmann's	Autosomal Dominant	First Decade	Epithelial Microcysts	BSCL, Keratoplasty
<b>BOWMAN'S</b>				
Reis-Buckler's	Autosomal Dominant	First Decade	Subepithelial Reticular Opacification	BSCL, Keratoplasty
<b>STROMAL</b>				
Granular	Autosomal Dominant	First or Second Decade	Gray/White Opacities	BSCL, Keratoplasty
Macular	Autosomal Recessive	First Decade	Hazy Stromal Opacification	BSCL, Keratoplasty
Lattice	Autosomal Dominant	First Decade	Refractile Branching Lines	BSCL, Keratoplasty
<b>ENDOTHELIUM</b>				
PPD	Autosomal Dominant	First Decade	Vesticular Lesions of the Posterior Cornea	BSCL, Hypertonics, Keratoplasty
Fuchs'	Autosomal Dominant	Fourth or Fifth Decade	Guttata w/Corneal Edema	BSCL, Hypertonics, DSAEK, Keratoplasty

(BSCL) Bandage Soft Contact Lens, (PTK) Phototherapeutic Keratotomy, (ASP) Anterior Stromal Puncture, (DSAEK) Descemet's Automated Endothelial Keratoplasty

### Bowman's Layer

**Reis-Buckler's Corneal Dystrophy** is an autosomal dominant dystrophy that presents in the first decade of life. It's characterized by subepithelial reticular changes that progress until middle age (Figure 3). Visual loss can result secondary to opacification and

erosions.

**Lattice Dystrophy** is an autosomal dominant dystrophy that presents as refractile lines in the anterior stroma during the first decade of life. These lines will eventually branch and develop deeper into the stroma. The overlapping effect will give the appear-

**The prognosis is generally very good, and only rarely is vision affected. An important note is that patients who have PPD have an increased risk of developing glaucoma.**

irregular astigmatism. These patients can suffer from episodic erosions, which you can manage with bandage soft contact lenses. You may consider surface, lamellar, or penetrating keratoplasty in the worst cases, and recurrence is possible.

### Stroma

**Granular Dystrophy** is an autosomal dominant dystrophy that typically presents in the first or second decade of life. Grayish white opacities form in the central anterior stroma with clear intervening space (Figure 4). The peripheral cornea is almost never affected.

As the dystrophy progresses, the lesions can become larger and more numerous with the intervening stroma remaining hazy. At this point vision is usually affected. Consider lamellar or penetrating keratoplasty if the patient's vision becomes disabled. Only rarely will this dystrophy migrate anterior enough to induce erosions.

**Macular Dystrophy** is the rarest of the stromal dystrophies discussed because it is autosomal recessive. Initially the anterior stroma becomes hazy starting in the first decade of life, progressing to opacified lesions. Unlike granular dystrophy, it's more likely to also affect the peripheral cornea, and the patient's visual prognosis is worse. Penetrating keratoplasty may be necessary for the worst cases, and recurrence is always a possibility. These patients are rarely prone to

ance of a lattice design. Besides visual loss, these patients are prone to erosions, which you can treat with bandage lenses as needed. Penetrating keratoplasty may be necessary if visual acuity drops below a functional level, and recurrence is possible.

### Endothelium

**Posterior Polymorphous Dystrophy (PPD)** is a dystrophy of the endothelium that is mostly dominantly inherited. It's characterized by vesicles deep into the cornea that may be isolated individual lesions, multiple ones that have coalesced, or broad bands that resemble train tracks (Figure 5). Some of these lesions may appear blister-like and have a gray white halo around them. Although both eyes are almost always affected, the severity of the dystrophy may be very asymmetrical. In some patients the expressivity of this dystrophy may be so mild that you could miss it on a routine slit lamp examination.

The prognosis is generally very good, and only rarely is vision affected. In the most severe cases corneal edema may occur, which you can manage with hypertonic solutions or ointments as necessary. An important note is that patients who have PPD have an increased risk of developing glaucoma.

**Fuchs' Endothelial Dystrophy** is unusual in that it has a late onset usually not observed or affecting the patient until the fifth decade. In some cases it has a

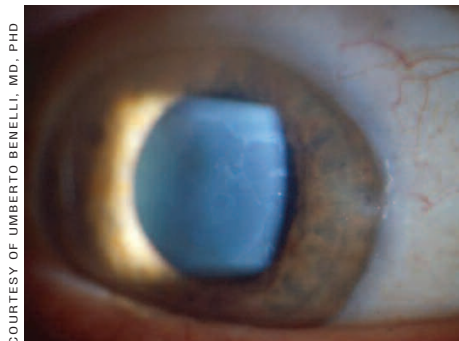


Figure 2. Maps of Epithelial Basement Membrane Dystrophy.

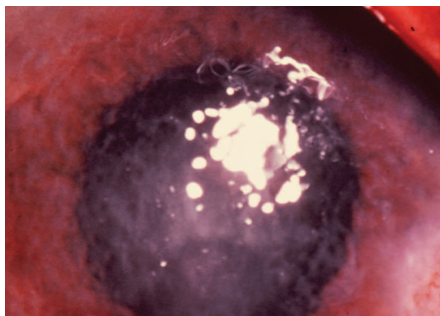


Figure 3. Subepithelial reticular opacification of Reis-Buckler's Corneal Dystrophy.

COURTESY OF UMBERTO BENEILLI, MD, PHD

COURTESY OF CURT KELLEY, MD

dominant mode of inheritance with incomplete penetrance. Fuchs' dystrophy is characterized by guttata, which are refractile excrescences on the posterior cornea (Figure 6). Guttata form secondary to abnormal functioning endothelial cells and can occur as the result of aging, trauma or inflammation.

Fuchs' dystrophy is diagnosed when nonfunctioning endothelium causes corneal edema. Stromal and eventually epithelial edema will result in decreased visual acuity. Patients' vision will be worse upon awakening because of the additional edema induced by nocturnal lid closure, but will improve during the day. Treatment early on involves addressing the swollen cornea with hypertonic solutions and ointment. With extreme epithelial edema, bullae may form and cause pain and photophobia. Bandage soft contact lenses may provide temporary relief. However, these patients require careful follow-up care to reduce the risk of stromal neovascularization or infectious keratitis. If at some point vision degrades to a disabling level, surgery should be considered.

Previously, the only surgical option for Fuchs' dystrophy was penetrating keratoplasty (PK). A new procedure termed Descemet's Stripping Automated Endothelial Keratoplasty (DSAEK) may offer these patients another option. As the name implies, Descemet's is stripped off and replaced with donor tissue. The primary advantage of DSAEK over PK is that it may allow for quicker visual recovery and induce less regular and irregular astigmatism because minimal suturing is required.

Often, patients who have Fuchs' dystrophy will have visually disabling cataracts as well. If the Fuchs' dystrophy is moderate or advanced, then the patient may have both a cataract extraction and corneal transplant combined into the same surgery. If the Fuchs' dystrophy is mild, then the patient may proceed with only the cataract extraction. However, sometimes the surgery will cause a dramatic worsening of the

Fuchs' changes and the patient will require a subsequent corneal transplant.

### Bandage Soft Contact Lenses

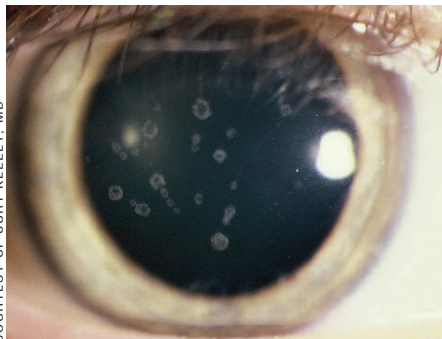
Disposable lenses revolutionized the treatment and management of patients who have corneal erosions. A soft contact lens on the eye not only covers the corneal defect, which can make the patient much more comfortable, but it can also help with healing by acting as a barrier between the blinking lids and healing epithelium.

The next advancement that has made a significant impact in the care of these patients is the availability of high-Dk silicone hydrogel contact lenses for therapeutic purposes. FDA approved therapeutic lenses are CIBA Vision's

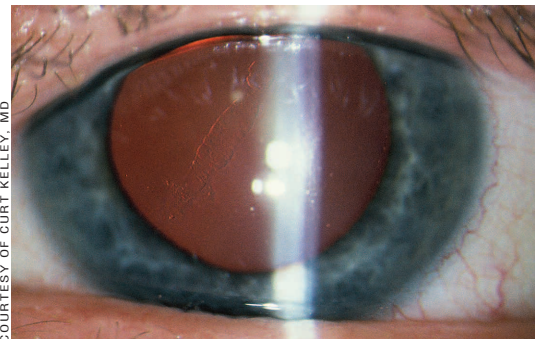
Night & Day contact lenses, Vistakon's Acuvue Oasys contact lenses and Bausch & Lomb's PureVision contact lenses. Vistakon has recently released a plano version of Acuvue Oasys that the company will market specifically for use as a bandage lens.

Practitioners often ask how these lenses should fit or, in other words, how much should the lenses move during blinking. It's important to remember that part of the lens' purpose is to prevent mechanical irritation to the healing cells, so if the lens moves too much you may lose some of what you were trying to accomplish in the first place. However, avoid adherence because most of these patients will wear these lenses on an extended wear basis and if a lens

**A soft contact lens on the eye not only covers the corneal defect, but it can also help with healing.**



**Figure 4. Stromal opacities in Granular Dystrophy.**



**Figure 5. Retroillumination of broad bands in Posterior Polymorphous Dystrophy.**

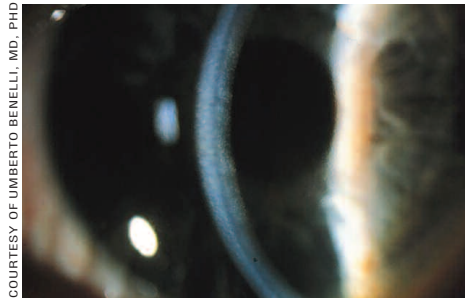
becomes sealed, then the patient will be prone to keratitis.

Begin with the steeper of the base curve radii of your lens of choice and evaluate the lens fit. If there is no lens movement with blinking and if you are un-

able to manually move the lens off of center using the patient's lid, then default to the flatter base curve or switch brands. Evaluate the patient one-to-three days later to reassess the fit, as these lenses can tighten significantly.

### Genetic Counseling

Genetic counseling is something to consider for any serious inherited medical disorder. A majority of the corneal dystrophies have autosomal dominant inheritance, so it follows that affected patients' children will have a 50 percent chance of developing the dystrophy if the other parent is not affected. This type of information is obviously much more critical if the prognosis is guarded, as is the case for patients who have Meesmann's, Reis-Buckler's, Granular and Lattice dystrophies. Even though surgical intervention is an option for any of these dystrophies, recurrence secondary to cell migration is always possible. However,



**Figure 6. Guttata in direct and proximal illumination in Fuch's Endothelial Dystrophy.**

it's also important to keep in mind that the severity of the disease expression can vary for each individual affected.

Patients with epithelial basement membrane dystrophy, Fuchs' and posterior polymorphous dystrophies are rarely counseled because not all cases are known to be autosomal dominant and generally the prognosis is good.

Patients who have macular dystrophy have a poor prognosis, but are unlikely to pass this dystrophy on because it is autosomal recessive. Practitioners can always refer patients and their families to a professional genetic counselor for further evaluation and education. **CLS**

*Special Acknowledgement to Drs. Curt Kelley and Beth Travis for their assistance with this article.*

*To obtain references for this article, please visit <http://www.clspectrum.com/references.asp> and click on document #151.*